STICHTING WERKGROEP ANTIBIOTICABELEID

The Dutch Working Party on Antibiotic Policy (SWAB) recommendations for the diagnosis and management of COVID-19 associated pulmonary aspergillosis

This evidence-based document is a supplement to the SWAB guidelines for the Management of Invasive Fungal Infections, revised version December 2017.

Committee:

N.M.A. Blijlevens,[1] R.J.M. Brüggemann,[2] J.J.W.M. Janssen,[3] D.W. de Lange,[4] J.F. Meis,[5] A.M.L. Oude Lashof,[6] M.H.E. Reijers,[7] B.J.A. Rijnders,[8] J.A. Schouten,[9] F.L. van de Veerdonk,[10] T.S. van der Werf,[11] T.F.W. Wolfs,[12] A.R.H. van Zanten,[13] and P.E. Verweij (chair).[14] The committee was supported by J.B. Buil[14] for literature review and writing and editing of the draft documents.

[1]Department of Hematology, Radboud University Medical Center, Nijmegen; [2]Department of Clinical Pharmacy, Radboud University Medical Center, Nijmegen; [3]Department of Hematology, Amsterdam University Medical Center, location VUmc, Amsterdam; [4]Department of Intensive Care, University Medical Center Utrecht, Utrecht; [5]Department of Medical Microbiology and Infectious Disease, Canisius Wilhelmina Hospital, Nijmegen; [6]Department of Infectious Diseases, Maastricht University Medical Center, Maastricht; [7]Department of Pulmonology, Radboud University Medical Center, Nijmegen; [8]Department of Medical Microbiology & Infectious Diseases, Erasmus Medical Center, Rotterdam; [9]Department of Intensive Care, Radboud University Medical Center, Nijmegen; [10]Department of Internal Medicine, Radboud University Medical Center, Nijmegen; [11]Department of Internal Medicine, Division of Infectious Diseases, University Medical Center Groningen, Groningen; [12]Wilhelmina Children's Hospital, University Medical Center Utrecht, Utrecht; [13]Department of Intensive Care Medicine, Gelderse Vallei Hospital, Ede; [14]Department of Medical Microbiology, Radboud University Medical Center, Nijmegen.

©2021 SWAB

www.swab.nl

Download van SWAB.nl | 2026-01-07 22:39

Contents

Introduction and methodology 3
Key questions 6
1. What is the case definition of COVID-19 associated pulmonary aspergillosis? 6
2. What is the optimal approach towards diagnosing or refuting CAPA in patients with COVID-19? 7
3. What is the reported incidence of *Aspergillus* pneumonia in patients with COVID-19? 10
4. What are the host- / risk factors that are associated with COVID-19 associated pulmonary aspergillosis (CAPA)? 12
5. What is the optimal antifungal choice for patients with proven or high likelihood of COVID-19 and suspected *Aspergillus* pneumonia? 14
6. How should invasive *Aspergillus* tracheobronchitis be managed in CAPA patients? 16
7. What is the role of immunomodulating agents in the management of CAPA in ICU patients? ... 17
Final considerations 18
Recommendations 20
Flow chart 21
Practical guidance for antifungal drug administration and drug target concentrations 23
References 24

CONCEPT

Download van SWAB.nl | 2026-01-07 22:39

Introduction and methodology

General introduction

Soon after the start of the COVID-19 pandemic, reports of suspected invasive pulmonary aspergillosis (IPA) complicating COVID-19 appeared. Although initial reports from China were not specific regarding the frequency and identification of fungal pathogens causing secondary infection in COVID-19 patients, reports from Europe indicated that *Aspergillus* was frequently cultured in airway samples from COVID-19 patients admitted to the ICU. IPA secondary to influenza was recognized as a clinical entity over the last years in patients admitted to the intensive care unit (ICU) with respiratory failure. Cases of influenza associated pulmonary aspergillosis (IAPA) were observed in 19% of influenza patients in the ICU in the Netherlands and Belgium.[1] The mortality rate was 51% in a retrospective multicenter cohort study compared to 28% in influenza patients without IAPA.[1] Characteristics of IAPA are listed in **Table 1**.

Table 1. Characteristics of influenza associated pulmonary aspergillosis (IAPA).

Characteristic	**Ref.**
IAPA occurs in 16% - 23% of patients with influenza in the ICU	1-3
IAPA develops in 32% of influenza patients with EORTC/MSGERC host factor compared to 14% in EORTC/MSGERC negative influenza patients in the ICU.	1
Between 30% and 78% of IAPA patients have no underlying EORTC/MSGERC host factor	1-4
IAPA occurs within 48 hrs of ICU admission in the majority of patients (early IAPA, co-infection) but is less frequently observed at a later point as well (late IAPA, secondary infection)	1-3,5
Between 30% and 56% of IAPA patients present with invasive *Aspergillus* tracheobronchitis	3,4
IAPA occurs in patients with influenza A as well as influenza B infection	1
Influenza is an independent risk factor for IAPA	1
Use of corticosteroids before ICU admission was independently associated with IAPA. Other risk factors include higher APACHE II score and male sex	1,3
Serum galactomannan is positive in 57% to 78% of IAPA patients	1-4
Serum Beta-D-glucan is positive in 82% of IAPA patients	4
BAL galactomannan is positive in 88% - 100% of IAPA patients	1-3
BAL *Aspergillus* culture is positive in 63%-89% of IAPA patients and 100% of patients with invasive tracheobronchitis	1-4
Azole resistance has been reported in IAPA with a frequency up to 29%	2
ICU mortality of IAPA is 51%-61% compared to 28% in influenza patients without IAPA	1-4
ICU mortality was 90% in influenza patients with invasive *Aspergillus* tracheobronchitis compared to 44% in influenza patients with other forms of IAPA.	4

Download van SWAB.nl | 2026-01-07 22:39

Based on the emerging risk of IAPA and the high frequency in the Netherlands, a recommendation was given in the SWAB guidelines for the Management of Invasive Fungal Infections (revised version December 2017):[6]

Recommendation 17	ICU patients with confirmed influenza should undergo sampling for serum galactomannan. It is recommended that ICU patients with confirmed influenza and radiologic abnormalities on chest X-ray should undergo bronchoscopy and BAL for galactomannan and culture. In case of tracheobronchitis, a positive serum galactomannan or a positive BAL galactomannan (index ≥0.8), patients should be treated with combination azole+echinocandin or azole+L-AmB therapy. Monotherapy with L-AmB is considered as a second choice in these patients. If cultures reveal no *Aspergillus* growth, galactomannan-positive BAL material should be tested by PCR for the presence of Cyp51 mutations. ICU patients with influenza and negative aspergillus serum and bronchoscopy/BAL screening, and non-ICU influenza patients should undergo (repeat) serum and bronchoscopy/BAL diagnostics if new respiratory complications or clinical worsening occur, or if sputum/tracheal *Aspergillus* colonization cultures are positive.

The increasing number of reports on *Aspergillus* superinfections in critically ill COVID-19 patients as well as the frequent detection of *Aspergillus* species or galactomannan (GM) in airway samples from critically ill COVID-19 patients, resulted in uncertainty about its clinical relevance as well as the best diagnostic and treatment strategies of these patients. Below we will use the term COVID-19 associated pulmonary aspergillosis (CAPA) when we refer to patients considered to have a tissue invasive infection with *Aspergillus*.

The current evidence was reviewed based on the following seven key questions:

Table 2. Key questions

1. What is the case definition of COVID-19 associated pulmonary aspergillosis?
2. What is the preferred approach towards diagnosing or refuting CAPA in patients with COVID-19?
3. What is the risk of *Aspergillus* pneumonia in patients with COVID-19?
4. Are there host/risk factors that are associated with CAPA?
5. What is the treatment of choice for patients with CAPA?
6. How should invasive *Aspergillus* tracheobronchitis be managed in CAPA patients?
7. What is the role of immunomodulating agents in the management of CAPA in ICU patients?

Conflicts of interest policy and funding

The Guidelines Committee would like to thank all individuals and societies who contributed to the development of these guidelines. Members of the preparatory committee reported the following potential conflicts of interest: NMAB…..; RJMB has received unrestricted grants, speaker fees or consultancy fees from Amplyx, Astellas, F2G, Gilead, Munidipharma, MSD and Pfizer. All contracts were with Radboudumc and all invoices were paid to Radboudumc; JJWMJ has no conflicts of interest; DWdL has no conflicts of interest; JFM received grants or speaker fees from F2G, Gilead and United Medical; AMLOL no conflicts of interest; MHER has no conflicts of interest; BJAR has received research grants

Download van SWAB.nl | 2026-01-07 22:39

from Gilead Sciences, outside the submitted work; JAS has no conflicts of interest; FLvdV has no conflicts of interest; TSvdW has no conflicts of interest; TFWW has no conflicts of interest; ARHvZ has no conflicts of interest; PEV has received unrestricted grants, speaker fees or consultancy fees from MSD, Pfizer, F2G, Gilead Sciences, Munidipharma and Thermofisher. All contracts were with Radboudumc and all invoices were paid to Radboudumc.

Methodology

The current addendum was based on seven key questions considering population, intervention, comparison, and outcomes (PICO) relevant for the Dutch clinical setting (**Table 2**). For each key question we developed short evidence summaries after searching PubMed and other sources considered relevant. The evidence was subsequently assessed using the Grading of Recommendations Assessment, Development, and Evaluation (GRADE) system as described in the SWAB sepsis guideline (**Figure 1**).[7,8]

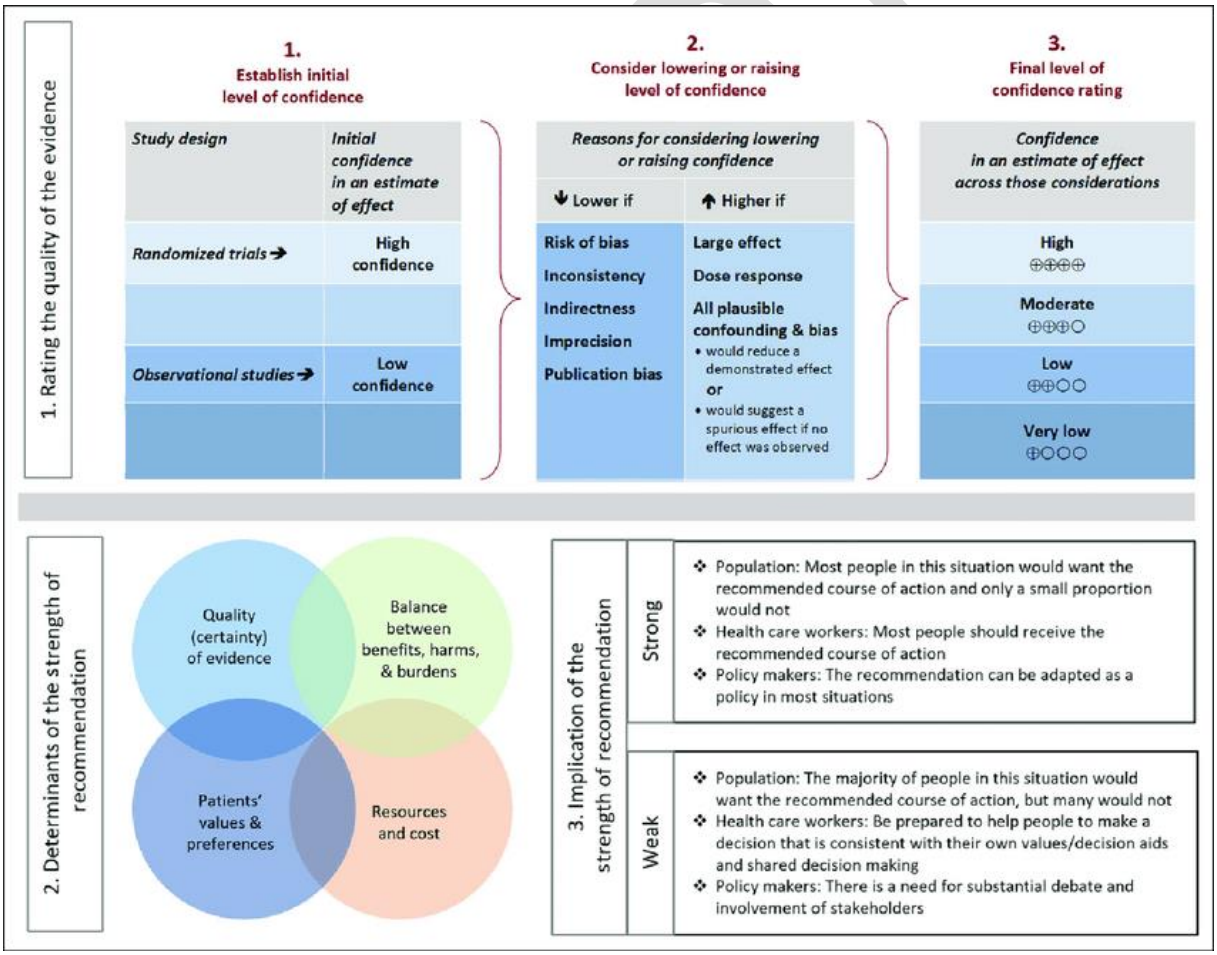

Figure 1. Overview of GRADE methodology. Approach and implications to rating the quality of evidence and strength of recommendations using the Grading of Recommendations Assessment, Development and Evaluation (GRADE) methodology.

The PubMed search strategy included ((coronavirus and 2020) or COVID-19 or SARS-CoV-2) and (Aspergillus* or aspergillosis* or CAPA) and included publications until December 15th 2020. When available, in-press publications not yet available on PubMed were included as well. Case-reports were excluded. In addition, unpublished cohort data were used from a multicenter CAPA registry study

Download van SWAB.nl | 2026-01-07 22:39

conducted in Belgium and the Netherlands. Quality of evidence for clinically relevant outcomes was graded from high to very low. A multidisciplinary committee formulated recommendations after structured discussions as strong or weak. The committee anticipated on limited high-quality evidence due to the recent emergence of SARS-CoV-2. When evidence could not be obtained, recommendations were provided on the basis of opinions and experiences with other viral pneumonias, notably influenza (good practice statements, GPS). Based on this process, we formulated 13 recommendations on the management of patients with a proven COVID-19 and *Aspergillus* colonization or a suspected or proven CAPA (see recommendations below).

Key questions

1. What is the case definition of COVID-19 associated pulmonary aspergillosis?

Evidence summary

A rapidly increasing number of papers on CAPA in COVID-19 patients admitted to the ICU are being reported in the literature. One problem is the lack of a consensus CAPA case definition, and various definitions have been used to classify CAPA. The invasive fungal infection case definition of the European Organization for Research and Treatment of Cancer (EORTC) / Mycosis Study Group Education and Research Consortium (MSGERC) is rarely applicable because it only applies to patients with a specific host factors, which are typically absent in patients suspected of having CAPA and due to the fact that the ICU-setting was excluded in the definition document.[9] Several studies have used the algorithm that was proposed by Blot et al. to distinguish between IPA and *Aspergillus* colonization in the ICU.[10] As the classification is based on a positive culture, sometimes revised definitions were used which include the biomarker GM to classify patients in addition to those with a positive culture. Other papers have used the criteria which were used by Schauwvlieghe et al.[1] to classify patients with IAPA. Recently, an expert group proposed a case definition to classify patients with IAPA. This case definition has also been used to classify patients with CAPA.[11] Finally, a consensus CAPA case definition was published by the European Confederation for Medical Mycology (ECMM) and the International Society for Human and Animal Mycology (ISHAM),[12] categorizing patients as proven, probable and possible CAPA. This document has only been published very recently and has not yet been used to classify CAPA patients. Furthermore, as described below, as long as the literature regarding autopsy and biopsy proven cases of CAPA remains very limited, the sensitivity and specificity of these definitions remains uncertain. As proven IPA relies on the demonstration of invasive growth of *Aspergillus* hyphae, there is little variation between definitions regarding this category. Variation in the probable category is notably relating to host factors, clinical factors (including radiologic imaging) and mycological criteria.[12]

Conclusions

A consensus CAPA case definition has been published which aimed to improve standardization and comparability of clinical studies. Due to the recent publication of the case definition and lack of proven CAPA cases, the sensitivity and specificity of these consensus definitions remains unclear.

Download van SWAB.nl | 2026-01-07 22:39

2. What is the optimal approach towards diagnosing or refuting CAPA in patients with COVID-19?

Evidence summary

Mycology

Demonstration of tissue invasive growth of septate hyphae and identification of *Aspergillus* through PCR or culture is considered the gold standard of proven IPA. This would require obtaining tissue through an invasive procedure or at autopsy. However, particularly during the first months of the pandemic, invasive diagnostic procedures have been discouraged due to the assumed risk of health care associated infection via aerosolization. This may explain the limited number of biopsy or autopsy proven CAPA cases (six) so far (**Table 3**). However, another possible explanation of the limited number of proven CAPA cases, despite the frequent documentation of *Aspergillus* species by culture, PCR or antigen testing in airway samples from critically ill COVID-19 patients may be that tissue invasion is indeed less frequent .

Table 3. Reported proven CAPA cases.

Sex / age	Underlying condition	Procedure	Respiratory GM/ culture	Highest serum GM	Ref.
M, 38	Obesity, hypercholesterolemia	Biopsy during bronchoscopy	BAL: >2.8 / *A. fumigatus*	0.3	[13]
M, 62	Diabetes	Biopsy during bronchoscopy	BAL: 2 / *A. fumigatus*	0.2	[13]
M, 73	Obesity, diabetes, hypertension, hypercholesterolemia	Biopsy during bronchoscopy	BAL: >2.8 / *A. fumigatus*	0.1	[13]
M, 77	Diabetes, chronic kidney disease, hypertension, pemphigus foliaceus	Biopsy during bronchoscopy	BAL: 2.79 / *A. fumigatus*	0.1	[13]
M, 71	Hypertension, diabetes, chronic kidney disease	Autopsy, molecular ID *A. penicillioides*	BAL: not performed	4.3	[14]
M, 73	Obesity, diabetes, hypertension, atrial fibrillation	Autopsy	Bronchial aspirate: *A. fumigatus*	positive	[15]

As invasive aspergillosis commonly presents as pulmonary infection, bronchoscopy with bronchial alveolar lavage (BAL) has become the most important tool to diagnose IPA. BAL samples have been validated for microscopy (using optical brighteners such as Blankophor P or calcofluor white), *Aspergillus* culture, detection of GM and *Aspergillus* DNA for species identification and detection of azole resistance markers (AsperGenius). Detection of *Aspergillus* antigen may take place through ELISA test (Platelia Aspergillus) or through lateral flow device (LFD) point-of-care tests that allow rapid

Download van SWAB.nl | 2026-01-07 22:39

detection of *Aspergillus* antigen (IMMY and OLM Diagnostics). Alternatively beta-D-glucan (BDG), which is a panfungal marker, may be detected in serum of patients with IPA.

An important issue in performing diagnostic procedures in COVID-19 patients has been the risk of aerosolization associated with bronchoscopy and BAL. Although bronchoscopy has generally been discouraged in COVID-19 patients, evaluation for co-infection is considered an indication to perform this procedure,[16] provided that adequate preventive measures are taken to protect health care workers.[17] In addition, exclusion of co-infection is considered relevant before starting corticosteroid treatment in COVID-19 patients with secondary clinical (respiratory) worsening that is attributed to pulmonary fibrosis or to organizing (non-infectious) pneumonia (also called Cryptogenic Organizing pneumonia, COP). Due to restricted availability of bronchoscopy, alternative specimens and procedures have been used, including testing of sputum, bronchial (BA)/ tracheal aspirates (TA) and non-bronchoscopic bronchial lavage (NBL).[12] Important drawbacks of these specimens include sampling of the upper respiratory tract rather than lower respiratory tract, lack of validation of *Aspergillus* biomarkers for these specimens, and inability to visualize the airways, which is critical to diagnose invasive *Aspergillus* tracheobronchitis. However, during the second wave availability of BAL has increased and the procedure is now safely used in most centers. An overview of the performance of *Aspergillus* diagnostics in reported case series is shown in **Table 4**.

Table 4. Overview of performance of diagnostic tests in CAPA

Country	**# of CAPA cases**	**BAL (#positive / #performed)**	***Aspergillus* species**	**TA/BA (#positive / #performed)**	**Serum (#positive / #performed)**	**Ref.**
France	9	Culture 5 / 7 GM 2 / 7 PCR 3 / 7	*A. fumigatus* (7)	Culture 2 / 2 GM - PCR 2/ 2	GM 1 / 9 BDG 4 / 8	18
Germany	5	Culture 1 / 3 GM 3 / 3 PCR 3 / 3	*A. fumigatus* (4)	Culture 2 / 3 GM ND PCR 1 / 2	GM 2 / 5 BDG -	19
NL	6	Culture 2 / 3 GM 3 / 3 PCR -	*A. fumigatus* (5)	Culture 3 / 3 GM - PCR -	GM 0 / 3 BDG -	20
Belgium	6	Culture 5 / 6 GM 5 / 6 PCR -	*A. fumigatus* (5), *A. flavus* (1)	Culture - GM - PCR -	GM 1 / 5 BDG -	13
Italy	30	Culture 19 / 30 GM 30 / 30 PCR 20 /30	*A. fumigatus* (16), *A. niger* (3), *A. flavus* (1)	Culture - GM - PCR -	GM 1 / 30 BDG -	21
UK	19	Only NBL performed; Denominator not reported	*A. fumigatus* (9), *A. versicolor* (1)	Denominator not reported	Denominator not reported	22

Download van SWAB.nl | 2026-01-07 22:39

Belgium	4	Culture 4 / 4* GM 4 / 4 PCR 2 /2	Not specified		GM - BDG -	[23]
Switzerland	3	Culture - GM - PCR -	*A. fumigatus* (3)	Culture 3 / 3 GM - PCR 1 / ?	GM 1 / ? BDG 1 / ?	[24]
France	19	Culture 7 / 9 GM 7 / 9 PCR -	*A. fumigatus* (14), *A. calidoustus* (1), *A. niger* (1)	Culture 9 / 10 GM - PCR -	GM 1 / 12 BDG -	[25]
Pakistan	5	Not specified	*A. fumigatus* (1), *A. flavus* (4), *A. niger* (1)	Not specified	GM 0 / 5 BDG 1 / 5	[26]
USA	4	Not specified	*A. fumigatus* (4)	Not specified	GM 1 / 3 BDG -	[27]
France	7	Culture not specified / 5 GM 3 / 5 PCR 2 / 5	*A. fumigatus (5)*	Not specified	GM 1 / 7 BDG 2 / 7	[33]

*BAL and BA were not distinguished.

Overall, BAL GM was positive in 57 of 64 (89%) of CAPA patients, while BAL culture was positive in 43 of 59 (73%). It should be noted that positive GM was considered entry criterion in the study of Bartoletti et al, which included 30 patients.[21] *Aspergillus* PCR in BAL was positive in 30 of 47 (64%) CAPA patients. Serum GM was positive in 7 of 71 (10%) patients.[21] The performance of LFD tests has been studied in ICU-patients,[28] and one study compared the performance of the Sona Aspergillus Galactomannan Lateral Flow Assay (IMMY) with that of the Platelia Aspergillus (Biorad) in TA obtained from CAPA patients.[29] However, as bronchoscopy was not performed in this study, a reliable classification of CAPA patients was not achieved.

Imaging

The typical appearance of COVID-19 includes peripheral, bilateral, ground-glass opacities with or without consolidation or visible intralobular lines (i.e. crazy paving) in early stages; multifocal ground glass opacities of rounded morphology with or without consolidation or crazy paving at peak stage; reverse halo sign as well as other findings of organizing pneumonia at late stages are observed as well.[30] Many signs of COVID-19 pneumonia can mimic CAPA, and vice versa, and lesions suggestive of CAPA may be hidden. Radiological findings that were previously shown to be sufficiently specific to diagnose IPA in immunocompromised patients are the halo sign, air-crescent sign, cavitating lung lesions and well-defined intrapulmonary nodule(s). In ICU patients with influenza cavitating lung lesions and well-described nodule(s) are also considered useful. Whether or not, any of these criteria can help in distinguishing *Aspergillus* colonization from infection in COVID-19 patients is as yet uncertain. Indeed, an intrinsic part of severe COVID-19 is intravascular thrombosis due to

Download van SWAB.nl | 2026-01-07 22:39

endotheliopathy, which can result in infarction and cavitating lesions as well as the halo sign.[12] Therefore, the role of imaging as a reliable criterion for diagnosing CAPA is probably limited. Importantly, CT may contribute to diagnose other reasons for respiratory deterioration. Nevertheless, for critically ill COVID-19 patients new nodules with cavitation or halo sign or consolidations have been recommended to trigger a diagnostic work-up for CAPA.[31] Autopsy data of a sufficient number of patients with these radiological findings present in the days preceding death are needed in order to improve our understanding of the radiology of CAPA.

Conclusions

- Very few biopsy or autopsy proven cases of CAPA have been reported. Therefore, definite conclusions on the diagnostic characteristics of a single diagnostic test or combinations of tests cannot be made (very low quality of evidence).
- The performance of TA or NBL for diagnosing CAPA remains unclear. These specimens are not validated for the use of GM, PCR and BDG detection and do not allow diagnosis of invasive *Aspergillus* tracheobronchitis (very low quality of evidence).
- BAL GM may be the most reliable test to diagnose CAPA but a positive BAL GM test should not be considered definite proof of CAPA (low quality of evidence).
- Serum GM was positive in very few patients (<10%), but if positive is indicative of CAPA (low quality of evidence).
- The role of imaging as a reliable criterion for diagnosing CAPA is limited (very low quality of evidence).

3. What is the reported incidence of *Aspergillus* pneumonia in patients with COVID-19?

Evidence summary

With the limitations described above regarding the definitions of CAPA in mind, the reported frequencies of CAPA can be found in **Table 5**.

Table 5. Reported characteristics of cohort studies of CAPA in ICU-patients that utilized bronchoscopy.

Country	Case definition	CAPA frequency	Time to first Asp. positive sample after ICU admission in days (range)∞	Ventilated	Proven/probable /putative	Ref.
France	EORTC/MSGERC (if immunocompromised)[9] and IAPA[2]	9 / 27 (33%)	Not specified	27 / 27	0 / 1 / 8	18
France*	Modified IAPA[11] and EORTC/MSGERC[9]	21 / 366 (5.7%)	6 (1 -15)	246 / 366	0 / 21 / 0	32
Germany	Modified *AspICU*[10]	5 / 19 (26%)	Not specified	5 / 5	0 / - / 5	19
NL	Modified IAPA[11]	6 / 31 (19%)	10 (3 – 28)	6 / 6	0 / 3 / 3	20

Download van SWAB.nl | 2026-01-07 22:39

Belgium	AspICU[10]	6 / 34 (21%)	8 (2 – 16)	6/6	4 / - / 2	[13]
Italy	Modified IAPA[11]	30 / 108 (28%)	4 (2 – 8) days * (study used screening protocol)	30 / 30	0 / 30 / -	[21]
	AspICU[10]	19 / 108 (18%)	8 (0 – 35)†	19 / 19	0 / - / 19	
UK	*AspICU*[10]	8 / 135 (6%)		7 / 8	0 / - / 8	[22]
	IAPA[1]	20 / 135 (15%)		15 / 20	0 / - / 20	
	Own definition	19 / 135 (14%)		14 / 19	0 / - / 19	
Belgium	Modified *AspICU*[10]	4 / 131 (3%)	4	4 / 4	0 / - / 4	[23]
Switzerland	Modified IAPA[11]	3 / 80 (4%)¥	6 (3-8)	3 / 3	0 / 1 / 2	[24]
France	Modified *AspICU*[10]	19 / 106 (18%)	11 (2-23)	18 / 19	0 / - / 19	[25]
France	EORTC/MSGERC (if immunocompromised)[9] and IAPA[2]	7 / 145 (5%)	10 (median)	27 / 27	0 / 0 / 7	[33]

*Includes cohort of Alanio et al.[18]

¥80 mechanical ventilated patients of a total of 118 patients admitted to the ICU.

†of 16 patients with multiple *Aspergillus* cultures positive.

∞Time to positivity: Antinori et al. culture sample taken at day 4 positive.[15] Ghelfenstein-Ferreira et al. culture positive with *A. fumigatus* of sample taken at day 6 after ICU admission.[34] Meijer et al. recovered *A. fumigatus* from a tracheal aspirate culture at ICU admission.[35] Mitaka et al. found that the 6 patients were mechanically ventilated for a mean of 6.8 days (range 1-14 days) before *Aspergillus* isolation. The two patients described by Helleberg had growth of *A. fumigatus* in respiratory samples 1 and 5 days after starting mechanical ventilation.[36]

Overall, 10 CAPA case series in the ICU reported 120 CAPA cases in 1,155 COVID-19 patients (10%, range between 3% and 33%). Only in four cases CAPA was proven, while the majority had a probable or putative diagnosis. One study from the Netherlands reported 6 CAPA cases in a cohort of 31 COVID-19 patients admitted to the ICU, of which three cases could be classified as probable CAPA.[16] Yet, a subsequent report from the same hospital reported on the results of postmortem pathology findings in these patients. The premortem diagnosis of CAPA could not be histologically confirmed. This however, does not exclude CAPA because no autopsy was performed but rather blinded percutaneous lung biopsies were evaluated.[37] A recent, yet unpublished cohort of 520 COVID-19 patients admitted to the ICU in centers in Belgium and the Netherlands during the first wave, showed that 41 patients (8%) could be classified as proven or probable CAPA according to the new consensus definitions.[38]

The cohort studies show that the vast majority of ICU patients that were diagnosed with CAPA were mechanically ventilated, although this may be explained by the fact that diagnostic procedures like BAL are rarely performed in non-ventilated patients with COVID-19. Furthermore, the majority of patients developed CAPA on average between day 4 and 11 after ICU admission. The study of Bartoletti which involved systematic bronchoscopy on day 0 and 7 of ICU admission indicated that 14 of 108 (13%) patients were BAL GM positive (index >1) at ICU admission.[21]

Download van SWAB.nl | 2026-01-07 22:39

Conclusions

- Observational studies on CAPA in COVID-19 patients reported frequencies between 3% and 33% in the ICU, using variable case definitions (very low quality of evidence).
- CAPA is almost exclusively reported in mechanically ventilated patients and can be diagnosed early as well as late after ICU admission (low quality of evidence).

4. What are the host- / risk factors that are associated with COVID-19 associated pulmonary aspergillosis (CAPA)?

Evidence summary

Case series published to date show that only a minority of patients have traditional EORTC/MSGERC host factors (**Table 6**). Three patients (2%) were reported with a hematological malignancy, two (1,5%) with other malignancies and five (4%) with solid organ transplantation. One study identified the presence of an EORTC/MSGERC host factor and solid organ transplantation as significant risk for invasive fungal infection. [33]

Table 6. Underlying diseases and identified risk factors for CAPA in published case series.

Country	# of CAPA cases	EORTC/MSGERC host factor (# pts)	Other underlying diseases	Identified risk factors	Ref.
France	9	Myeloma + steroids (1), steroids (1)	Hypertension, obesity, diabetes, ischemic heart disease, asthma	N.A.	18
France*	21	Solid organ transplant (1), myeloma (1)	Hypertension, diabetes, obesity, coronary disease, asthma	Cumulative corticosteroid dose ≥100 mg higher in CAPA (OR, 3.7; IC95% 1.0 -9.7)	32
Germany	5	Not present	Hypertension, obesity, hypercholesterolemia, diabetes, COPD, emphysema	N.A.	19
NL	6	Not present	COPD, asthma, cardiomyopathy	N.A.	20
Belgium	6	AML (1)	Hypertension, obesity, hypercholesterolemia, diabetes, HIV	N.A.	13
Italy	30	Malignancies (2), solid organ transplant, chronic steroid treatment	Hypertension, obesity, hypercholesterolemia, diabetes, coronary disease, cerebrovascular disease, chronic kidney disease, COPD	Chronic steroid therapy was significantly more frequent in CAPA compared to non-CAPA (p=0.02)	21

Download van SWAB.nl | 2026-01-07 22:39

UK	19	Hematological malignancy (1), corticosteroid therapy (15) – dose and duration not specified	Vasculitis, essential hydrocortisone thrombocytopenia, diabetes, chronic respiratory illness, solid cancer, autoimmune disease, obesity, hypertension, Alzheimer disease, chronic kidney disease,	Association between multiple positive *Aspergillus*/BDG positive test and the use of high dose corticosteroids (p=0.007) and chronic respiratory condition (p=0.05)	22
Belgium	4	Not present	Obesity, chronic kidney disease	N.A.	23
Switzerland	3	Not present	Hypertension, obesity, diabetes, pulmonary fibrosis, asthma	N.A.	24
France	19	Not present	Hypertension, diabetes, malignancy, COPD, asthma, tuberculosis, cardiopathy, ABPA, schizophrenia, glaucoma, HIV	N.A.	25
France	7	Kidney transplantation (2), liver transplantation (1), steroids (1)	Hypertension, obesity, diabetes, tabagism, dyslipidemia	Preexisting host factor (p=0.03), solid organ transplant (p=0.004), long term (>3weeks) corticosteroid therapy (any dose)(p=0.01)	33

*Includes cohort of Alanio et al.[18]

Three cohort studies have identified risk factors for CAPA. Chronic steroid treatment (at dosages higher than or equivalent to prednisone 16 mg/day for at least 15 days) was found to be significantly more frequent in patients with CAPA compared to those without CAPA.[21] The use of high dose corticosteroids (dose not defined) and the presence of chronic lung disease were associated with multiple positive *Aspergillus* tests.[22] A third cohort found that corticosteroids administered at any dose for > 3 weeks was a risk factor for invasive fungal infection.[33] A forth study did not find that high dose corticosteroids was associated with CAPA risk (11.5% versus 28.6%; p=0.08), but observed cumulative dose ≥100 mg to be higher among CAPA patients.[32]

All but few of the reports on CAPA come from a setting where corticosteroid therapy was not yet the standard of care but rather the exception. Since the publication of the Recovery trial, corticosteroid therapy has become the standard of care for all patients admitted with severe COVID-19. [39] Therefore, the data regarding the impact as well as the magnitude of the impact of corticosteroid use on the incidence of CAPA should be considered preliminary. In particular, the question remains if a certain cumulative dose is required and to what extent a 10 day regimen of dexamethasone that was used in the recovery trial and has become the standard of care in the Netherlands poses a significant risk for CAPA.

Download van SWAB.nl | 2026-01-07 22:39

Conclusions

- Most CAPA patients lack EORTC/MSGERC host factors (low quality of evidence).
- Multiple cohort studies show that corticosteroid therapy is associated with increased risk for CAPA (low quality of evidence).
- Host factors that have been implicated to increase the risk for CAPA include, any EORTC/MSGERC host factor, solid organ transplant or chronic respiratory disease (very low quality evidence).

5. What is the optimal antifungal choice for patients with proven or high likelihood of COVID-19 and suspected *Aspergillus* pneumonia?

Evidence summary

Despite the difficulty in distinguishing between *Aspergillus* colonization and invasive infection, several studies have shown excess mortality in *Aspergillus* positive COVID-19 patients in the ICU (**Table 7**). In the study of Bartoletti et al, of the 30 CAPA patients, 16 received antifungal therapy of which 13 received voriconazole.[21] Fourteen patients did not receive antifungal therapy due to post mortem diagnosis (7 patients) or due to clinical decision (7 patients). Survival of patients treated with voriconazole was 54% (7 of 13), and for those not receiving voriconazole 41% (7 of 17)(p=.39).[21] A relationship between initial BAL GM index and 30-day survival was noted. The odds of death within 30 days of ICU admission increased 1.41-fold (1.10–1.81; P = .007) for each point increase in the initial BAL GM index. When adjusted for age, need for renal replacement therapy, and SOFA score at ICU admission, the initial BAL GM index was still independently associated with increased odds of death within 30 days of ICU admission (OR, 1.44; 95% CI, 1.08–1.94; P = .014).[21] In the study of White et al., mortality rates ranged from 46.7% (95% CI, 24.8–69.9) in CAPA patients receiving appropriate antifungal therapy to 100% (95% CI, 51.1–100) in patients not receiving appropriate antifungal therapy.[22] In the cohort from Belgium and the Netherlands, 20 of 41 (48.8%) CAPA patients died compared to 135 of 476 (28.2%) of COVID-19 without CAPA (p<0.05). (Janssen, unpublished)[38] Furthermore, in a validation cohort from France including 304 COVID-19 ICU patients, CAPA mortality was 42.9% (9 of 21) compared to 21.2% (60 of 283) in COVID-19 ICU patients without CAPA (p<0.05). (Janssen, unpublished)[38] Van Biesen et al. found a mortality of 22.2% in patients with CAPA based on NBL and 15.1% in patients without CAPA.[40] In the study of Dupont, 3 of 9 (33%) of antifungal-treated patients compared to 5 of 10 (50%) untreated patients died at day 42.[25]

Table 7. Mortality in COVID-19 patients with CAPA compared with controls.

Country	Case definition	# of CAPA patients	Mortality in CAPA	Mortality in control	Ref.
France	EORTC/MSGERC (if immunocompromised)[9] and IAPA[1]	9	44%	39% (p=0.99)	[18]
France†	Modified IAPA[11] and EORTC/MSGERC[9]	21	71.4%	36.8% (p<0.01)	[32]
Italy	IAPA[11]	30	44% (day 30)	19% (day 30)(p=.002)*	[21]
	AspICU[10]	19	74%	26% (p<.001)	

Download van SWAB.nl | 2026-01-07 22:39

UK		19	58% (day 77?)	38%	[22]
NL	CAPA[12]	41	48.8%	28.2% (p<0.05)	[38]

***** Diagnosis of CAPA was associated with 30-day mortality from ICU admission (OR, 3.53; 95% CI, 1.29–9.67; P = .014), even after adjustment for age (OR, .99; 95% CI, .94–1.06; P = .99), need for renal replacement therapy (OR, 3.02; 95% CI, 1.11–8.19; P = .015), and SOFA score at ICU admission (OR, 1.38; 95% CI, 1.07–1.73; P = .004) with a logistic regression model.[21]
† Includes cohort of Alanio et al.[18]

On the other hand, patients with CAPA may survive without receiving antifungal therapy. As indicated above, 7 of 17 (41%) CAPA patients who were not treated with voriconazole survived in the case series reported by Bartoletti et al.[8] Alanio and colleagues described 7 patients with putative (6) or probable (1) CAPA who did not receive antifungal therapy, of which 5 survived.[18] Survival may be due to various factors, including absence of invasive disease. Indeed in one study tissue biopsies showed no evidence for CAPA, despite that most patients were classified as probable cases.[37] These observations might implicate that in some critically ill COVID-19 patients positive *Aspergillus* tests reflects colonization rather than invasive disease.

Azole resistance. Three cases of azole-resistant CAPA have been reported, one from the Netherlands,[35] one from France,[34] and one from Ireland.[41] In all cases the TR_{34}/L98H resistance mutation was detected, which is associated with environmental resistance selection. Nethmap resistance surveillance in the Netherlands indicates that in all five participating University Medical Centers the azole resistance rates are ≥10% in *A. fumigatus* (average azole resistance rate 12.5%),[42] while in five teaching hospitals the resistance rates are lower (average resistance rates 6.1%). There are currently no indications that the risk for azole-resistant infection will differ from that in other ICU patients.

There are no studies that investigate the optimal antifungal therapy of CAPA in COVID-19 patients in the ICU. We therefore refer to the SWAB 2017 guideline for the management of invasive fungal infections for primary treatment choices. Combination antifungal therapy is recommended for a period of 2 weeks, unless triazole resistance (switch to liposomal amphotericin B) or triazole-susceptibility (continue with voriconazole or isavuconazole) is documented. Patients who have improved clinically after 2 weeks, are stable and have unknown azole resistance may be stepped down to azole monotherapy under strict follow-up.

Pharmacological considerations. Therapeutic drug monitoring (TDM) is an important component in triazole treatment of patients with CAPA. Critical illness with (multi) organ failure predisposes patients to a high degree of variability in drug exposure. This is further complicated by factors such as drug-drug interactions and the frequent use of renal replacement techniques as well as extracorporeal membrane oxygenation. Also protein binding, specifically of posaconazole and isavuconazole, may be altered although little is known about the impact of hypoalbumenia.
Abovementioned variables make it difficult to predict adequate drug exposure in individual patients. In line with the SWAB guideline on treatment of invasive fungal infections TDM is recommended on a weekly basis for all triazole drugs.[6] TDM is strongly recommended for voriconazole and posaconazole. The advice for monitoring of posaconazole is a stronger recommendation compared to the SWAB guideline. This is due to the high likelihood of lower posaconazole concentrations caused by the induction of dexamethasone [https://go.drugbank.com/drugs/DB01234; assessed January 10 2021]. Although the evidence for this interaction is not very strong and the clinical relevance subject to debate, there is a hypothetical mechanism to support such an interaction. Finally, TDM should also be considered for isavuconazole.

Download van SWAB.nl | 2026-01-07 22:39

Pharmacokinetic drug-drug interactions will play an important role. Triazole drugs are mostly perpetrator drugs but can be victim drugs as well. In the Netherlands drug-drug interactions are monitored by electronic prescribing systems with direct feedback to the clinician. Nevertheless, these systems might not identify drug interactions with new or experimental drugs. A highly recommended and reliable source for drug interactions can be found at https://www.covid19-druginteractions.org/. This data source setup by the University of Liverpool together with the Radboudumc provides the latest insights into relevant drug interactions including the azole drugs.

Next to pharmacokinetic interactions, pharmacodynamic interactions (drug with similar toxicity profiles) may be relevant. These interactions include interactions between (lipid) formulations of amphotericin B and nephrotoxic drugs, potassium losing agents and posaconazole, and many more. Please consult your hospital pharmacist for management of these interactions.

(See Practical guidance for antifungal drug administration and drug target concentrations)

Conclusions

- There is currently not enough evidence to draw any definitive conclusion on the optimal antifungal treatment strategy for patients with proven or high likelihood of COVID-19 and suspected *Aspergillus* co-infection.
- For antifungal therapy of patients with CAPA the SWAB 2017 recommendations for treatment of invasive aspergillosis should be followed.
- Concomitant administration of dexamethasone and posaconazole may reduce posaconazole plasma concentrations (very low quality of evidence).
- Many variables impact on triazole drug exposure in critically ill patients, supporting the use of TDM (very low quality of evidence).

6. How should invasive *Aspergillus* tracheobronchitis be managed in CAPA patients?

Evidence summary

Invasive *Aspergillus* tracheobronchitis was found to be a frequent and highly lethal manifestation of IAPA, which may be due in part to epithelial erosion of trachea and bronchi due to the influenza virus. Autopsy studies indicate that focal white patches may be present in the trachea and large bronchi of 92% of COVID-19 patients.[43] Histology shows mucosal ulceration with mixed inflammatory cell infiltration, including neutrophils and fibrin. This is likely to be due to viral tropism as the epithelium of the conducting airways was shown to support the replication of SARS-CoV.[44] Local epithelial damage may provide a port of entry for *Aspergillus* to cause invasive airway disease. Pseudomembranous plaques or ulcers were visible in 6 of 30 (20%) patients with CAPA,[21] and bronchial ulcers reported in two of 8 *Aspergillus* positive COVID-19 patients, but the patients in the latter study were not classified according to published definitions.[45] In the Dutch-Belgian cohort of 41 CAPA cases, 4 (10%) proven invasive *Aspergillus* tracheobronchitis cases were registered.[38] These data indicate that the frequency of invasive *Aspergillus* tracheobronchitis in CAPA is probably lower than observed in IAPA. However, the diagnosis of invasive *Aspergillus* tracheobronchitis is made through visualization of plaques in the

Download van SWAB.nl | 2026-01-07 22:39

airways, and since the use of bronchoscopy has been restricted, tracheobronchitis cases may be underreported.

The mortality of invasive *Aspergillus* tracheobronchitis is unknown in CAPA, but was reported to be as high as 90% in IAPA patients.[4] There are no data on mortality associated with invasive *Aspergillus* tracheobronchitis in CAPA. Systemic antifungal therapy alone might not be sufficient to effectively treat this disease manifestation due to intraluminal growth of the fungus. Inhaled (liposomal) amphotericin B has been recommended in these cases as adjunctive therapy by the IDSA.[46] To date only one IAPA patient with invasive *Aspergillus* tracheobronchitis was reported to be treated with nebulized liposomal amphotericin B in addition to systemic antifungal therapy.[47]

Conclusions

- Invasive *Aspergillus* tracheobronchitis is occasionally observed in patients with COVID-19 (very low quality of evidence).
- Invasive *Aspergillus* tracheobronchitis in CAPA is diagnosed through visual inspection and mucosal biopsy of suspected lesions (very low quality of evidence).
- Systemic antifungal treatment of invasive *Aspergillus* tracheobronchitis in critically ill COVID-19 patients is indicated, but there is little evidence to support additional nebulized liposomal amphotericin B therapy (very low quality of evidence).

7. What is the role of immunomodulating agents in the management of CAPA in ICU patients?

Evidence summary

Corticosteroids in influenza and other coronavirus respiratory syndromes have shown no benefit or possible harm.[48,49] Early consensus was against corticosteroids in COVID-19.[50] During the pandemic the RECOVERY trial, a meta-analysis of steroid trials by the WHO, and the REMAP-CAP trial have changed practice by showing benefit of corticosteroids in COVID-19 patients in the ICU.[39,51,52] RECOVERY reported that in over 6,000 patients the administration of 6 mg dexamethasone for ten days was associated with significantly reduced 28-day mortality.[39] This result was most pronounced among patients requiring mechanical ventilation (rate ratio = 0.65, 95% CI = 0.48 – 0.88, p = 0.0003) and changed clinical practice immediately. The question arose whether there would be additive effects of other immunomodulatory drugs on top of corticosteroids. Recently, REMAP-CAP showed that in an ICU population blocking the IL-6 pathway with tocilizumab or sarilumab could further reduce mortality and organ free support days in the ICU when started within 24 hours of admission to the ICU.[53] Median organ support-free days were 10 (interquartile range [IQR] -1, 16), 11 (IQR 0, 16) and 0 (IQR -1, 15) for tocilizumab, sarilumab and control, respectively. Hospital mortality was 28% (98/350) for tocilizumab, 22.2% (10/45) for sarilumab and 35.8% (142/397) for control. Again similar to corticosteroids there were no reports of increased adverse events, including secondary infections during treatment.[39,48,51,53]

Immune-modulation has thus become a cornerstone of treatment of COVID-19 in the ICU. And current practice will include combinations of corticosteroids and blocking IL-6 in critically ill patients. Although there is no evidence for increased frequency of IPA in this population with immunotherapy compared to no immunotherapy, the difficulty of diagnosing CAPA as outlined here and the fact that registrations

Download van SWAB.nl | 2026-01-07 22:39

of fungal infection complications are not optimal do not allow us to know whether the incidence of CAPA is the same, lower or higher in this COVID-19 population receiving immunotherapy. The risk factors identified for CAPA thus far do include corticosteroids and the population with the highest CAPA incidence was a study where over 70% of patients had received tocilizumab.[21] However the argument not to start immunomodulatory therapy in the ICU because of risk of CAPA is not valid given the reported beneficial effects in the ICU population.

When CAPA is diagnosed we do not have data which supports that stopping dexamethasone or other immune modulatory agents would be beneficial in addition to antifungal treatment. In light of the beneficial effects demonstrated in RCTs we therefore advise to continue immunomodulatory treatment. More data is needed on the incidence and significance of CAPA in COVID-19 patients in the ICU with immunomodulatory treatment.

Conclusions.

- There is insufficient data on the incidence and significance of CAPA in COVID-19 patients in the ICU with immunomodulatory treatment (very low level of evidence).
- There is no evidence to stop immunomodulatory therapy once CAPA is diagnosed (very low level of evidence).

Final considerations

Most publications to date have involved patient cohorts during the first corona wave and the studies were hampered by the lack of a consensus case definition and the reluctance to perform bronchoscopy and invasive procedures, including autopsy. These factors have contributed to areas of uncertainty regarding the pathophysiology, diagnosis and management of CAPA. Upper respiratory tract specimens, such as TA and sputum, have been used to identify CAPA patients, but detection of *Aspergillus* in these specimens may represent respiratory tract colonization rather than invasive infection. Furthermore, sputum and TA are not validated for the detection of GM or *Aspergillus* DNA. The poor performance of serum biomarkers for the diagnosis of CAPA, underscores the need to obtain lower respiratory tract material to be able to diagnose CAPA. Increasing experience with bronchoscopy in critically ill CAPA patients, has shown that this procedure can be performed safely provided adequate infection prevention measures are taken to prevent exposure of health care workers to infectious aerosols. As bronchoscopy also allows visual inspection of the airways and thus enables the diagnosis of invasive *Aspergillus* tracheobronchitis, bronchoscopy and BAL remain the main diagnostic procedure to diagnose CAPA. In addition to diagnosing CAPA and other respiratory infections, BAL may also be useful to exclude CAPA in patients that require corticosteroid therapy, for instance for the treatment of COP or the prevention of pulmonary fibrosis.

Positive TA *Aspergillus* culture or any unexplained respiratory deterioration in critically ill COVID-19 patients are considered triggers to perform a bronchoscopy and BAL (flow chart). Antifungal therapy should be started as soon as possible. BAL GM results may be awaited if available the same day, but if not, antifungal therapy should be started pre-emptively while awaiting *Aspergillus* test results. In this setting, positive *Aspergillus* LFD tests may help to decide to promptly start antifungal therapy, but there are currently no test validation data in COVID-19 patients. Nevertheless, the performance of *Aspergillus* LFD tests in BAL in another ICU patient population was good.[28] The *Aspergillus* LFD test may be especially useful in treatment centers where regular GM tests are not routinely performed and samples must sent to other laboratories, extending the time to diagnosis.

Download van SWAB.nl | 2026-01-07 22:39

The use of dexamethasone for the standard treatment of COVID-19 might increase the risk for the development of CAPA, but an increased CAPA frequency during the second corona wave has not yet been reported in the literature. The need to administer corticosteroids for the treatment of COVID-19 and the associated risk for CAPA, present a dilemma in the management of critically ill COVID-19 patients. Although the decision to continue corticosteroids in critically ill patients who develop CAPA needs to be assessed on an individual patient basis, we believe that dexamethasone therapy should be continued for the timeframe as suggested by the SWAB guideline [54] if possible. This also applies to patients who are treated with high dose corticosteroid therapy for pulmonary fibroproliferation in the course of ICU stay and develop CAPA. Discontinuation or tapering of corticosteroids could be considered in patients that do not respond to antifungal therapy or with underlying EORTC/MSGERC host factors, although this is not supported by scientific data.

There are currently no CAPA cases reported in children, which may indicate that the risk to develop CAPA in this population is low. Other secondary fungal infections have been reported in critically ill COVID-19 patients, including candidemia, fusariosis, scedosporiosis and mucormycosis, and should be considered in critically ill COVID-19 patients with positive cultures.

The COVID-19 field is rapidly evolving and new COVID-19 treatment regimens such as the use of dexamethasone and/or immunotherapy may alter the risk for CAPA. Furthermore, autopsy studies are likely to increase our understanding of CAPA and help to validate case definition and diagnostic tests. As these developments are likely to have impact on our recommendations, we aim to update the recommendations when deemed necessary.

CONCEPT

Download van SWAB.nl | 2026-01-07 22:39

Recommendations

Recommendation	Strength	Quality of evidence
1. A CAPA diagnostic work up is recommended in mechanically ventilated COVID-19 patients with unexplained respiratory deterioration or a positive *Aspergillus* culture from the respiratory tract.	Strong	Low
2. We recommend maximum efforts to perform a bronchoscopy for inspection of the airways and bronchoalveolar lavage (BAL) to diagnose CAPA in patients with proven or high likelihood COVID-19 in the ICU.	Strong	Low
3. Screening of critically ill COVID-19 patients for serum GM or BDG is not recommended.	Strong	Low
4. There is no recommendation against or in favor of using lateral flow devices based assays for diagnosing CAPA.	Weak	Very low
5. Patients with visible plaques in trachea and bronchi should undergo mucosal biopsy or brush to diagnose invasive *Aspergillus* tracheobronchitis.	Strong	Low
6. Detection of *Aspergillus* in sputum and tracheal aspirate is considered insufficient evidence to support CAPA diagnosis, but warrants further diagnostics through bronchoscopy and BAL.	Strong	Low
7. Standard CT imaging is not recommended to refute or diagnose CAPA.	Weak	Very low
8. Antifungal therapy is indicated in patients with proven or probable CAPA.	Strong	Low
9. We recommend to follow the SWAB Management of Invasive Fungal Infections 2017 guideline on antifungal therapy of CAPA.	Strong	Low
10. We recommend not to stop concomitant dexamethasone or corticosteroid therapy in CAPA patients that require antifungal therapy.	Weak	Very low
11. We recommend to consider pre-emptive therapy for CAPA in patients in who(m) a BAL has been performed and BAL GM results are pending.	Weak	Very low
12. In patients with a negative BAL GM, discontinuation of pre-emptive antifungal therapy is recommended.	Weak	Very low
13. Therapeutic drug monitoring (TDM) is recommended in critically ill CAPA patients receiving triazole therapy.	Strong	Low

CONCEPT

Download van SWAB.nl | 2026-01-07 22:39

Flow chart

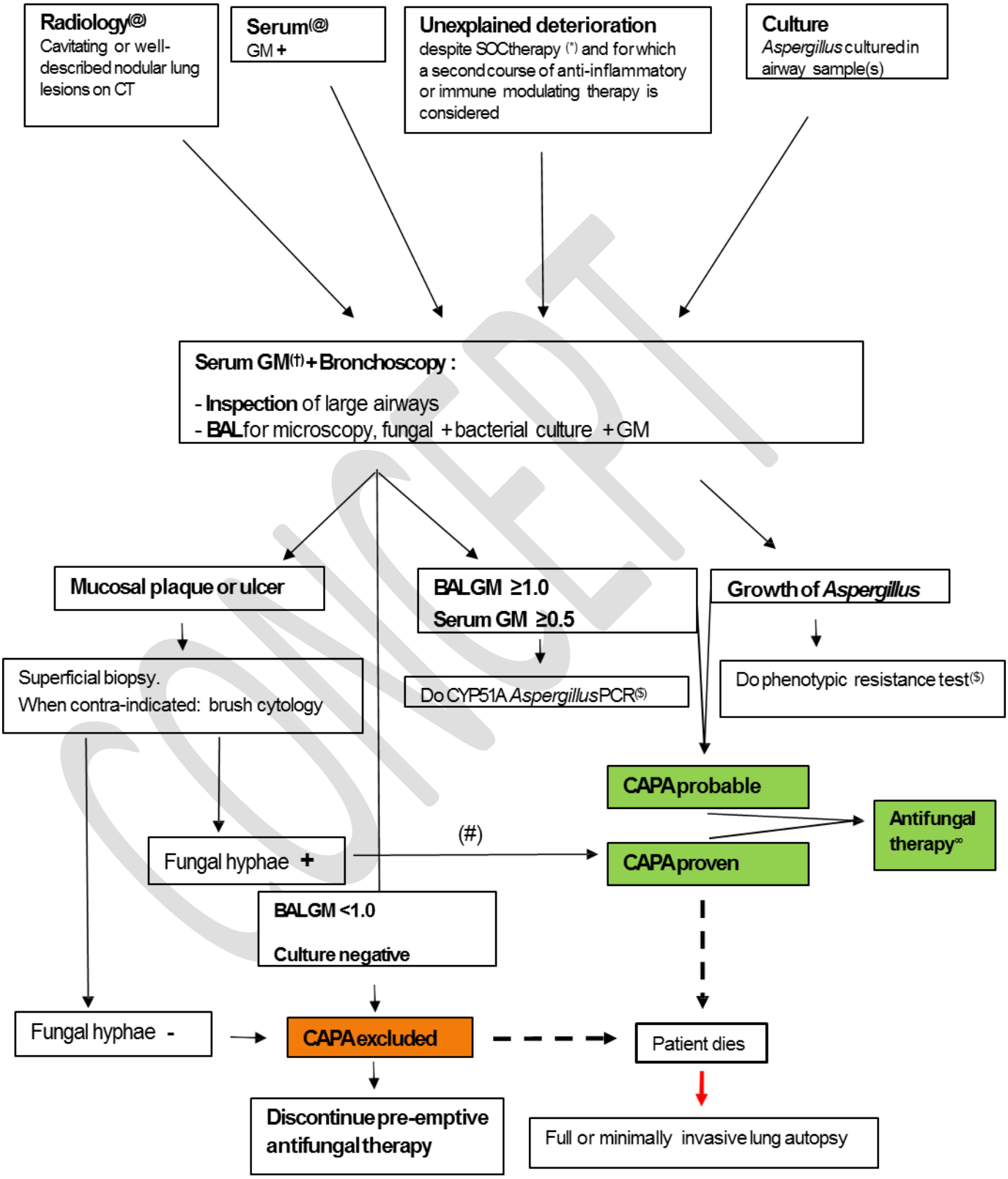

Proposed clinical guidance for the management of CAPA

Download van SWAB.nl | 2026-01-07 22:39

[@] This does not mean that a lung CT and serum GM testing should be standard of care for all ICU patients with COVID-19. Instead, the flow diagram is meant to be used when a CT is done during routine patient care and shows cavitating or well-described nodular lung lesions or a serum GM is measured for a suspected CAPA and turns out positive.

[*] SOC = Standard of care. The SOC of COVID-19 is likely to change in the future but for now it includes thromboembolic prophylaxis, therapy with dexamethasone, exclusion of pulmonary embolism with CT. Other causes of clinical respiratory deterioration may also need to be have been excluded: pneumothorax, atelectasis, progressive pulmonary fibrosis.

[$] If there is growth of *Aspergillus,* phenotypic resistance testing can be used e.g. with VIPcheck on site or at a mycology reference laboratory. In culture negative but GM positive BAL samples, the CYP51A *Aspergillus* PCR can be used to exclude the presence of the 2 most frequent resistance mutations that confer azole resistance in the Netherlands (TR_{34}/TR_{46} pattern).

[#] Formally, only when septate hyphae size 2.5 to 4.5 µm in diameter are seen *AND* the presence of *Aspergillus* DNA is documented as well, the infection is classified as proven CAPA. However, the presence of hyphae compatible with *Aspergillus* suffices to start antifungal therapy.

[†] Serum GM is generally negative, but increases the probability of CAPA if positive in combination with positive BAL GM.

It is recommended to start antifungal therapy as early as possible. If BAL test results are available the same day these can be awaited before antifungal therapy is started. If not, immediately available it is recommended to consider starting antifungal therapy pre-emptively while awaiting test results. Rapid LFD tests may be used to decide whether or not to start antifungal therapy, but due to lack of data the committee does not recommend against or in favor of this strategy. If the patient shows clinical signs of aspergillus tracheobronchitis, we recommend to repeat bronchoscopy once per week to evaluate the effect of antifungal therapy.

CONCEPT

Download van SWAB.nl | 2026-01-07 22:39

Practical guidance for antifungal drug administration and drug target concentrations

1. In the setting of gastro-intestinal dysfunction, intravenous voriconazole is preferred over oral voriconazole. The voriconazole solvent sulpha-butyl-ether-cyclodextrin (SBECD) is considered only to accumulate in the setting of poor renal function, but is not nephrotoxic itself.
2. We recommend against the use of posaconazole oral suspension.
3. Posaconazole intravenous administration should be done over a central venous catheter due to the very low pH of the intravenous solution.
4. Posaconazole tablets cannot be crushed and thus not be used for administration over the nasogastric tube.
5. Isavuconazole capsules can be opened and given over the nasogastric tube (expert opinion). The " syringe method" should be used as the drug has a very bad taste.
6. Lipid formulations of amphotericin B (typically Ambisome) is recommended over amphotericin B deoxycholate.
7. Special patient populations such as obese patients require attention with regards to risk of underdosing for posaconazole, isavuconazole and all echinocandins and risk of overdosing for voriconazole and liposomal amphotericin B.
8. Hepatic function should be monitored for all triazoles. Renal function should be monitored for liposomal amphotericin B. Electrolyte disturbances, specifically hypokalemia is frequently observed when using liposomal amphotericin B but also with posaconazole.
9. In all circumstances, trough concentrations should be assessed between day 3-5 after start of triazole therapy unless Model Informed Precision Dosing is used to derive the area-under-the-concentration time curve. However, in the absence of good population pharmacokinetic models, it is relatively unlikely that such a technique will be deployed.

Triazole drug target concentrations. An overview of target concentrations is presented in **Table 8**. The target concentrations are derived for the setting of azole-susceptible *Aspergillus* infection.

Table 8. Target plasma concentrations for triazoles.

Drug	Lower target	Upper target
Voriconazole	> 1.5 - 2 mg/L	< 4-6 mg/L
Posaconazole	>1 mg/L	3.75 mg/L * limited evidence to support higher concentrations
Isavuconazole	>2 mg/L	4 mg/L # marginal evidence to support higher concentrations

*The upper threshold for posaconazole is not well defined. For the oral suspension, the product leaflet recommends an upper limit of 3.75 mg/L for posaconazole. In clinical studies this threshold appeared safe. Recently new data has emerged on the use of intentional (in the setting of intermediate susceptible species) as well as occasional high concentrations of posaconazole supporting safety at higher exposures. [55]

Target concentrations for isavuconazole have not yet been clearly established. Currently, the exposure attained in patients responding to therapy is pursued which amounts to 2-4 mg/L. From the phase III studies, it was observed that toxicity occurred at an area under the concentration time curve of 233 mg*h/L.[56] This equals a trough concentration of about 9 mg/L. Therapeutic drug monitoring of liposomal amphotericin B is not warranted.

Download van SWAB.nl | 2026-01-07 22:39

References

1. Schauwvlieghe A, Rijnders BJA, Philips N, et al. Invasive aspergillosis in patients admitted to the intensive care unit with severe influenza: a retrospective cohort study. *The Lancet Respiratory medicine.* 2018;6(10):782-792.
2. van de Veerdonk FL, Kolwijck E, Lestrade PP, et al. Influenza-associated aspergillosis in critically ill patients. *American journal of respiratory and critical care medicine.* 2017;196(4):524-527.
3. Wauters J, Baar I, Meersseman P, et al. Invasive pulmonary aspergillosis is a frequent complication of critically ill H1N1 patients: a retrospective study. *Intensive Care Med.* 2012;38(11):1761-1768.
4. Nyga R, Maizel J, Nseir S, et al. Invasive tracheobronchial aspergillosis in critically ill patients with severe influenza. A Clinical Trial. *American journal of respiratory and critical care medicine.* 2020;202(5):708-716.
5. Vanderbeke L. Unpublished. In:2021.
6. Kullberg BJ, Blijlevens NM, Janssen JJWM, et al. SWAB guidelines for the management of invasive fungal infections. www.swab.nl/richtlijnen. Published 2017. Accessed 14 dec., 2017.
7. Guyatt GH, Oxman AD, Vist GE, et al. GRADE: an emerging consensus on rating quality of evidence and strength of recommendations. *BMJ (Clinical research ed).* 2008;336(7650):924-926.
8. Sieswerda E, Bax HI, Hoogerwerf JJ, et al. The Dutch Working Party on Antibiotic Policy (SWAB) guideline for empirical antibacterial therapy of sepsis in adults. *The Dutch Working Party on Antibiotic Policy (SWAB).* 2020.
9. Donnelly JP, Chen SC, Kauffman CA, et al. Revision and update of the consensus definitions of invasive fungal disease from the European Organization for Research and Treatment of Cancer and the Mycoses Study Group Education and Research Consortium. *Clinical infectious diseases : an official publication of the Infectious Diseases Society of America.* 2020;71(6):1367-1376.
10. Blot SI, Taccone FS, Van den Abeele AM, et al. A clinical algorithm to diagnose invasive pulmonary aspergillosis in critically ill patients. *American journal of respiratory and critical care medicine.* 2012;186(1):56-64.
11. Verweij PE, Rijnders BJA, Bruggemann RJM, et al. Review of influenza-associated pulmonary aspergillosis in ICU patients and proposal for a case definition: an expert opinion. *Intensive Care Med.* 2020;46(8):1524-1535.
12. Koehler P, Bassetti M, Chakrabarti A, et al. Defining and managing COVID-19-associated pulmonary aspergillosis: the 2020 ECMM/ISHAM consensus criteria for research and clinical guidance. *The Lancet Infectious diseases.* 2020.
13. Rutsaert L, Steinfort N, Van Hunsel T, et al. COVID-19-associated invasive pulmonary aspergillosis. *Annals of intensive care.* 2020;10(1):71.
14. Santana MF, Pivoto G, Alexandre MAA, et al. Confirmed invasive pulmonary aspergillosis and COVID-19: the value of postmortem findings to support antemortem management. *Rev Soc Bras Med Trop.* 2020;53:e20200401.
15. Antinori S, Rech R, Galimberti L, et al. Invasive pulmonary aspergillosis complicating SARS-CoV-2 pneumonia: A diagnostic challenge. *Travel Med Infect Dis.* 2020;38:101752.
16. Pritchett MA, Oberg CL, Belanger A, et al. Society for Advanced Bronchoscopy Consensus Statement and Guidelines for bronchoscopy and airway management amid the COVID-19 pandemic. *J Thorac Dis.* 2020;12(5):1781-1798.
17. Koehler P, Cornely OA, Kochanek M. Bronchoscopy safety precautions for diagnosing COVID-19 associated pulmonary aspergillosis-A simulation study. *Mycoses.* 2021;64(1):55-59.

Download van SWAB.nl | 2026-01-07 22:39

18. Alanio A, Delliere S, Fodil S, Bretagne S, Megarbane B. Prevalence of putative invasive pulmonary aspergillosis in critically ill patients with COVID-19. *The Lancet Respiratory medicine.* 2020;8(6):e48-e49.
19. Koehler P, Cornely OA, Bottiger BW, et al. COVID-19 associated pulmonary aspergillosis. *Mycoses.* 2020;63(6):528-534.
20. van Arkel ALE, Rijpstra TA, Belderbos HNA, van Wijngaarden P, Verweij PE, Bentvelsen RG. COVID-19-associated pulmonary aspergillosis. *American journal of respiratory and critical care medicine.* 2020;202(1):132-135.
21. Bartoletti M, Pascale R, Cricca M, et al. Epidemiology of invasive pulmonary aspergillosis among COVID-19 intubated patients: a prospective study. *Clinical infectious diseases : an official publication of the Infectious Diseases Society of America.* 2020.
22. White PL, Dhillon R, Cordey A, et al. A national strategy to diagnose COVID-19 associated invasive fungal disease in the ICU. *Clinical infectious diseases : an official publication of the Infectious Diseases Society of America.* 2020.
23. Sarrazyn C, Dhaese S, Demey B, Vandecasteele S, Reynders M, Van Praet JT. Incidence, risk factors, timing and outcome of influenza versus Covid-19 associated putative invasive aspergillosis. *Infection control and hospital epidemiology.* 2020:1-7.
24. Lamoth F, Glampedakis E, Boillat-Blanco N, Oddo M, Pagani JL. Incidence of invasive pulmonary aspergillosis among critically ill COVID-19 patients. *Clinical microbiology and infection : the official publication of the European Society of Clinical Microbiology and Infectious Diseases.* 2020;26(12):1706-1708.
25. Dupont D, Menotti J, Turc J, et al. Pulmonary aspergillosis in critically ill patients with Coronavirus Disease 2019 (COVID-19). *Medical mycology.* 2021;59(1):110-114.
26. Nasir N, Farooqi J, Mahmood SF, Jabeen K. COVID-19-associated pulmonary aspergillosis (CAPA) in patients admitted with severe COVID-19 pneumonia: An observational study from Pakistan. *Mycoses.* 2020;63(8):766-770.
27. Mitaka H, Perlman DC, Javaid W, Salomon N. Putative invasive pulmonary aspergillosis in critically ill patients with COVID-19: An observational study from New York City. *Mycoses.* 2020;63(12):1368-1372.
28. Mercier T, Dunbar A, Veldhuizen V, et al. Point of care aspergillus testing in intensive care patients. *Critical care (London, England).* 2020;24(1):642.
29. Roman-Montes ACM, Martinez-Gamboa A, Diaz-Lomeli P, et al. Accuracy of galactomannan testing on tracheal aspirates in COVID-19-associated pulmonary aspergillosis. *Mycoses.* 2020.
30. Lang M, Som A, Mendoza DP, et al. Detection of unsuspected Coronavirus Disease 2019 cases by computed tomography and retrospective implementation of the Radiological Society of North America/Society of Thoracic Radiology/American College of Radiology consensus guidelines. *J Thorac Imaging.* 2020.
31. Armstrong-James D, Youngs J, Bicanic T, et al. Confronting and mitigating the risk of COVID-19 associated pulmonary aspergillosis. *The European respiratory journal.* 2020;56(4).
32. Delliere S, Dudoignon E, Fodil S, et al. Risk factors associated with COVID-19-associated pulmonary aspergillosis in ICU patients: a French multicentric retrospective cohort. *Clinical microbiology and infection : the official publication of the European Society of Clinical Microbiology and Infectious Diseases.* 2020.
33. Fekkar A, Lampros A, Mayaux J, et al. Occurrence of invasive pulmonary fungal infections in severe COVID-19 patients admitted to the ICU. *American journal of respiratory and critical care medicine.* 2020;0(ja):null.
34. Ghelfenstein-Ferreira T, Saade A, Alanio A, et al. Recovery of a triazole-resistant Aspergillus fumigatus in respiratory specimen of COVID-19 patient in ICU - A case report. *Medical mycology case reports.* 2020.

Download van SWAB.nl | 2026-01-07 22:39

35. Meijer EFJ, Dofferhoff ASM, Hoiting O, Buil JB, Meis JF. Azole-resistant COVID-19-associated pulmonary aspergillosis in an immunocompetent host: a case report. *Journal of fungi (Basel, Switzerland).* 2020;6(2).
36. Helleberg M, Steensen M, Arendrup MC. Invasive aspergillosis in patients with severe COVID-19 pneumonia. *Clinical microbiology and infection : the official publication of the European Society of Clinical Microbiology and Infectious Diseases.* 2021;27(1):147-148.
37. Flikweert AW, Grootenboers M, Yick DCY, et al. Late histopathologic characteristics of critically ill COVID-19 patients: Different phenotypes without evidence of invasive aspergillosis, a case series. *J Crit Care.* 2020;59:149-155.
38. Janssen NAF. Unpublished In:2021.
39. Recovery Collaborative Group, Horby P, Lim WS, et al. Dexamethasone in hospitalized patients with Covid-19 - Preliminary Report. *The New England journal of medicine.* 2020.
40. Van Biesen S, Kwa D, Bosman RJ, Juffermans NP. Detection of invasive pulmonary aspergillosis in COVID-19 with non-directed bronchoalveolar lavage. *American journal of respiratory and critical care medicine.* 2020;202(8):1171-1173.
41. Mohamed A, Hassan T, Trzos-Grzybowska M, et al. Multi-triazole-resistant Aspergillus fumigatus and SARS-CoV-2 co-infection: A lethal combination. *Medical mycology case reports.* 2020.
42. De Greeff SC, Schoffelen AF, Verduin CM. NethMap 2020: Consumption of antimicrobial agents and antimicrobial resistance among medically important bacteria in the Netherlands in 2019 / MARAN 2020: Monitoring of Antimicrobial Resistance and Antibiotic Usage in Animals in the Netherlands in 2019. 2020.
43. Borczuk AC, Salvatore SP, Seshan SV, et al. COVID-19 pulmonary pathology: a multi-institutional autopsy cohort from Italy and New York City. *Mod Pathol.* 2020;33(11):2156-2168.
44. Jia HP, Look DC, Shi L, et al. ACE2 receptor expression and severe acute respiratory syndrome coronavirus infection depend on differentiation of human airway epithelia. *Journal of virology.* 2005;79(23):14614-14621.
45. Wang J, Yang Q, Zhang P, Sheng J, Zhou J, Qu T. Clinical characteristics of invasive pulmonary aspergillosis in patients with COVID-19 in Zhejiang, China: a retrospective case series. *Critical care (London, England).* 2020;24(1):299.
46. Patterson TF, Thompson GR, 3rd, Denning DW, et al. Practice guidelines for the diagnosis and management of aspergillosis: 2016 update by the Infectious Diseases Society of America. *Clinical infectious diseases : an official publication of the Infectious Diseases Society of America.* 2016;63(4):e1-e60.
47. Boots RJ, Paterson DL, Allworth AM, Faoagali JL. Successful treatment of post-influenza pseudomembranous necrotising bronchial aspergillosis with liposomal amphotericin, inhaled amphotericin B, gamma interferon and GM-CSF. *Thorax.* 1999;54(11):1047-1049.
48. Lansbury LE, Rodrigo C, Leonardi-Bee J, Nguyen-Van-Tam J, Shen Lim W. Corticosteroids as adjunctive therapy in the treatment of influenza: an updated Cochrane Systematic Review and meta-analysis. *Critical care medicine.* 2020;48(2):e98-e106.
49. Li H, Chen C, Hu F, et al. Impact of corticosteroid therapy on outcomes of persons with SARS-CoV-2, SARS-CoV, or MERS-CoV infection: a systematic review and meta-analysis. *Leukemia.* 2020;34(6):1503-1511.
50. Russell CD, Millar JE, Baillie JK. Clinical evidence does not support corticosteroid treatment for 2019-nCoV lung injury. *Lancet.* 2020;395(10223):473-475.
51. Angus DC, Derde L, Al-Beidh F, et al. Effect of hydrocortisone on mortality and organ support in patients with severe COVID-19: the REMAP-CAP COVID-19 corticosteroid domain Randomized Clinical Trial. *JAMA.* 2020;324(13):1317-1329.

Download van SWAB.nl | 2026-01-07 22:39

52. W. H. O. Rapid Evidence Appraisal for COVID-19 Therapies Working Group, Sterne JAC, Murthy S, et al. Association between administration of systemic corticosteroids and mortality among critically ill patients with COVID-19: a meta-analysis. *JAMA.* 2020;324(13):1330-1341.
53. Gordon AC. Interleukin-6 receptor antagonists in critically ill patients with Covid-19 - Preliminary report. *medRxiv.* 2021:2021.2001.2007.21249390.
54. Vollaard A, Gieling E, de Lange D, et al. SWAB - Medicamenteuze behandeling voor patiënten met COVID-10 (infectie met SARS-CoV-2). 2020.
55. Schauwvlieghe A, Buil JB, Verweij PE, et al. High-dose posaconazole for azole-resistant aspergillosis and other difficult-to-treat mould infections. *Mycoses.* 2020;63(2):122-130.
56. Maertens JA, Raad, II, Marr KA, et al. Isavuconazole versus voriconazole for primary treatment of invasive mould disease caused by *Aspergillus* and other filamentous fungi (SECURE): a phase 3, randomised-controlled, non-inferiority trial. *Lancet.* 2016;387(10020):760-769.

CONCEPT

Download van SWAB.nl | 2026-01-07 22:39